

Technical Note

Simplified Single-Portal V-Shaped SLAP Repair

Eduard Buess, M.D., and Constanze Schneider, M.D.

Abstract: We present a simplified and cost-effective method for repair of a type II SLAP lesion that requires only 1 working portal in the rotator interval—the lateral anterosuperior portal (LASP)—which is about 3 cm more lateral than the standard ASP. The rotator cuff tendon or muscle are not violated when using this portal, which provides an unproblematic 30° angle for the drill hole. The biceps root can be firmly reattached anteriorly and posteriorly using 1 double-loaded absorbable bone anchor with a suture eyelet. The first stitch is performed using a straight suture hook to pierce the anterior biceps root from the front. A PDS utility suture helps to shuttle the braided suture in a retrograde manner through the labrum. We then tie a sliding knot seating solidly on top of the labrum. The second stitch is placed with a 45° curved suture hook allowing us to pierce the labrum posteriorly to the biceps from above. Again, a sliding knot will be seated on top of the posterior biceps root, pressing it firmly onto the previously abraded bone. The completed repair looks like a V and produces secure fixation of the biceps, thus eliminating the peel-back phenomenon. **Key Words:** SLAP lesion—SLAP repair—Portals—Shoulder arthroscopy.

The interest in lesions of the superior labrum and biceps anchor has been rapidly increasing since Snyder's first description and classification of SLAP-lesions in 1990.¹ Many aspects of SLAP (superior labrum anterior and posterior) lesions remain controversial like the mechanism of injury and the technique of repair.² The symptoms are often confusing because of overlap with symptoms originating from concomitant partial or complete rotator cuff tears. In athletic patients, a SLAP lesion can present as a dead-arm syndrome.³ The most useful clinical tests seem to be the O'Brien and the Jobe relocation tests.⁴

A SLAP lesion can be found either isolated or

combined with all patterns of anterior, posterior, or multidirectional instability, and with rotator cuff tears. Its repair aims at restoring the hoop stress of the intact labral circle and the glenoid "suction cup" that enhances stability by means of adhesion and cohesion.^{3,4}

A type II SLAP lesion is considered significant according to Burkhart if the following signs are found at diagnostic arthroscopy: (1) an uncovered glenoid of 5 mm or more medial to the corner, (2) a displaceable vertex, and (3) a positive peel-back sign.³ The peel-back sign has proven to be very useful in our experience.

Numerous proposals for the technique of SLAP repair have been published, but suture anchors can now be considered as the state of the art. Different operative approaches to the superior glenoid have been advocated, e.g., through the rotator interval,⁵ through the rotator cuff,^{4,6} or through the supraspinatus muscle.⁷

Our purpose was to develop a reliable, fast, economical, and easy-to-teach technique for type II SLAP repair using 1 double-loaded suture anchor and the smallest number of portals and amount of disposable material possible.

From the Orthopedic Department, Sonnenhof Clinic, Berne, Switzerland.

Address correspondence and reprint requests to Eduard Buess, M.D., Buristrasse 11, CH-3006 Berne, Switzerland. E-mail: ebuess@shoulder-care.ch

© 2006 by the Arthroscopy Association of North America

Cite this article as: Buess E, Schneider C. Simplified single-portal V-shaped SLAP repair. *Arthroscopy* 2006;22:680.e1-680.e4 [doi:10.1016/j.arthro.2005.10.023].

0749-8063/06/2206-5158\$32.00/0

doi:10.1016/j.arthro.2005.10.023

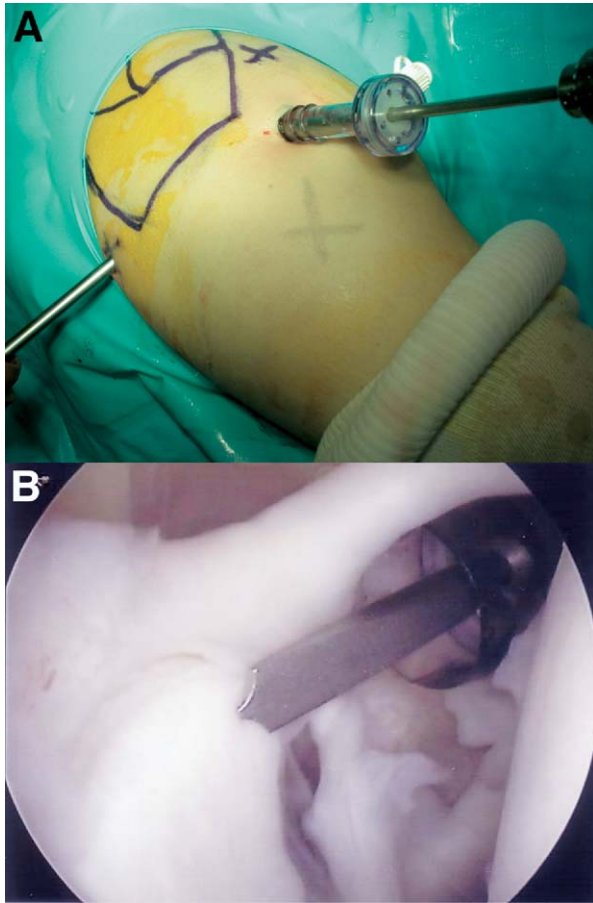


FIGURE 1. (A) Arthroscope in the posterior viewing portal with an 8.25-mm working cannula in the LASP closely related to the anterior edge of the acromion. (B) Drill bit inside cannula meeting the glenoid joint surface at a 30° angle. Drill hole may be 1 to 2 mm inside the articular cartilage.

SURGICAL TECHNIQUE

The patient is placed in the beach-chair position with 3 kg of anterior skin traction. After diagnostic evaluation with the arthroscope in the standard posterior portal and confirmation of a SLAP lesion type II we routinely perform the peel-back test as described by Burkhart and Morgan^{3,4} to get an impression of the biomechanical relevance of the SLAP lesion. In our experience, it is often not easy to distinguish between a type I lesion (to be debrided and left alone) and a type II lesion (to be repaired).

Once the decision is made to repair, we establish, in an outside-in fashion, a lateral anterosuperior portal (LASP), which is about 3 cm more lateral than the standard anterosuperior portal (Fig 1A) and passes directly above the superior glenohumeral ligament, as

close to the biceps and as lateral as possible. The anterior border of the supraspinatus tendon is left untouched. This portal provides an unproblematic 30° angle for the drill hole in relation to the glenoid joint surface (Fig 1B). After probing with a needle, we introduce a switching stick and equip the LASP with a 8.25-mm working cannula. No other portals are needed for the entire procedure.

The lesion is debrided with a shaver down to cancellous bone. After that, a 2.9-mm drill hole is established with a step-drill directly at the edge of the articular cartilage or 1 to 2 mm inside it. We then introduce an absorbable Panalok Loop anchor (DePuy Mitek, Norwood, MA) containing a suture eyelet loaded with a white No. 2 Panacryl and a green No. 2 Ethibond (Ethicon, Somerville, NJ) suture. The double-loaded anchor is pushed in and locked. The can-

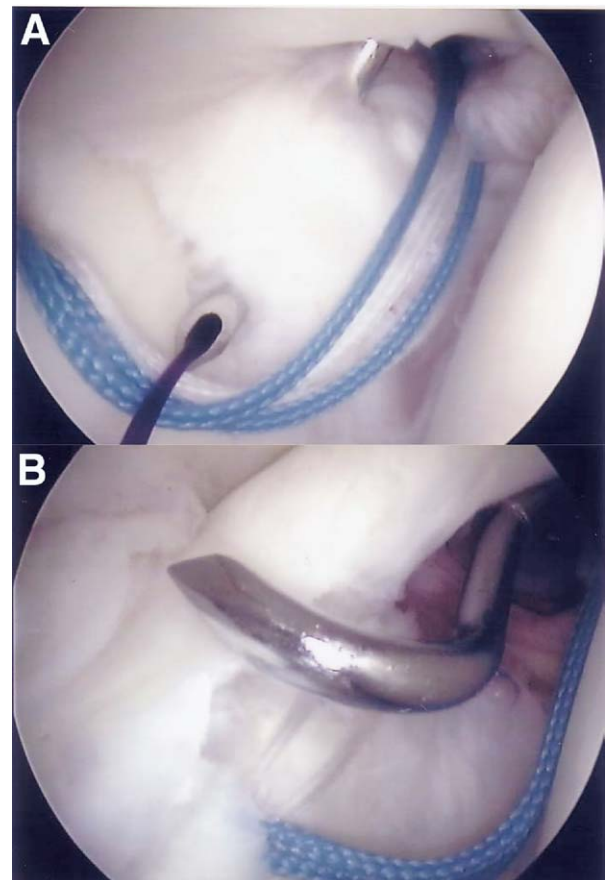


FIGURE 2. (A) The Spectrum suture hook “straight” piercing the anterior biceps root. The PDS utility suture strand is fed into the joint to retrieve the white Panacryl suture. (B) The suture hook “45° left curve” is ideal to pierce the (biomechanically more important) posterior biceps root.

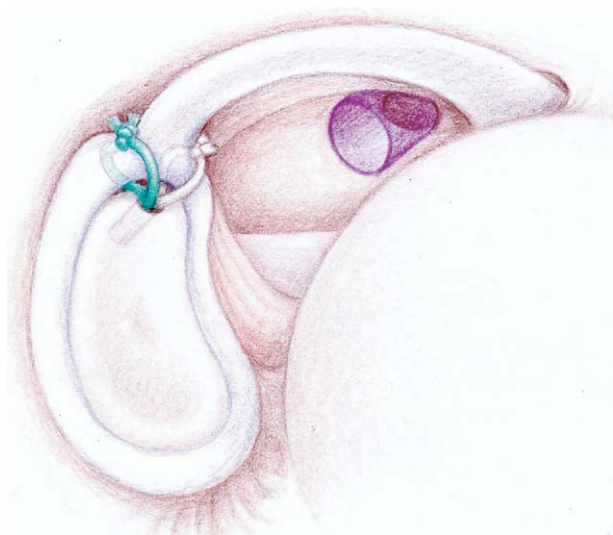

FIGURE 3. The completed V-type SLAP II repair.

nula is temporarily removed over the switching stick and then screwed in again, leaving the sutures outside the cannula. This step is important to avoid the cumbersome suture tangling.

The first stitch is performed using the Linvatec Spectrum suture hook “straight” (Linvatec, Largo, FL). The anterior biceps root is pierced from the front and a No. 0 PDS (Ethicon) suture transported about 20 cm into the joint (Fig 2A). The retrieving forceps is now used to bring the PDS together with 1 strand of the white suture out of the joint. Tying a simple knot with the PDS around the white braided Panacryl suture and pulling the other end will shuttle the braided suture in a retrograde manner through the labrum and out into the cannula. We retrieve the second white suture limb and tie a sliding knot seating solidly on top of the labrum.

Then the second stitch is placed with the suture hook “45° left curve” (for the right shoulder): the labrum is pierced posteriorly to the biceps from above (Fig 2B), the PDS fed into the joint, and the green

suture transported through the posterosuperior labrum in an identical fashion. The second sliding knot will be seated on top of the posterior biceps root and press this area of soft tissue firmly onto the bone. Placing the drill hole 1 to 2 mm inside the articular cartilage tends to enhance compression. Intentionally the stronger nonabsorbable Ethibond suture is used for the biomechanically more important posterior biceps root. The completed repair looks like a V (Fig 3) and produces a secure fixation of the biceps, thus eliminating the peel-back phenomenon.

Postoperative Care and Clinical Experience

The patient is kept in a sling for 4 weeks, external rotation with a stick is encouraged to prevent shoulder stiffness, and isometric cuff strengthening is started immediately. Ongoing, from week 5, range of motion is gradually increased and strengthening is intensified. Sports-related training is started after 4 months. If a rotator cuff repair has been performed as well, the rehabilitation scheme is similar, but delayed.

For several years we have routinely used 1 or 2 Panalok anchors for SLAP repair. However, the new Panalok Loop anchor gave us the opportunity to revise our technique. The technique described above has been used in 23 patients since December 2003, but only 5 of them had isolated SLAP repairs (Table 1). Three female patients with isolated SLAP lesions and a mean age of 30 years were reviewed 8 to 12 months postoperatively. Their Constant score improved by an average of 23 points from 54 preoperatively to 77 points. They were satisfied with the procedure and able to do sports at their preinjury level.

DISCUSSION

Most of the literature about SLAP lesions focuses on the overhead athlete,²⁻⁴ but we encounter SLAP lesions quite frequently in the average working population, especially together with rotator cuff tears. By

TABLE 1. Patient Characteristics

Sex and age	12 male 17–55 yr (38.8)		11 female 23–61 yr (34.7)	
History of trauma	Yes	19 (83%)	No	4 (17%)
SLAP isolated or combined	Isolated	5 (22%)	Combined	18 (78%) with:
			Rotator cuff repair	10
			Bankart repair	4
			Plication/shrinking	3
			Acromioclavicular resection	1

admitting that the SLAP lesion is enhancing the superior instability of the cuff-deficient shoulder, it appears logical that it is worthwhile to fix most type II SLAP lesions. If the shoulder is presenting with a large or massive rotator cuff tear and/or cartilage damages, however, we usually prefer “skillful neglect,” biceps tenodesis, or simple tenotomy.

Our technique uses only 1 working portal whereas other techniques described in the literature use 2 or 3.^{3,5-7} No switching of the arthroscope from posterior to anterior is needed.⁵ This single lateral anterosuperior portal (LASP) is situated at the superolateral corner of the rotator interval and does not violate the cuff like the Neviaser⁷ or Wilmington⁴ portals.

The drill hole can be placed at the correct angle and, with the appropriate suture hooks, the posterior and anterior biceps roots are readily reached and pierced in the desired direction. We prefer the suture hook to the penetrating forceps because of less trauma to the tendon itself and greater versatility, making the creation of additional portals unnecessary.

A double-loaded anchor allows for fixation of both the anterior and the biomechanically more important posterior biceps root. Thus the peel-back sign is eliminated. Other techniques need 2 anchors to achieve this purpose.^{3,6} Abrasion at the suture eyelet is another important issue that only recently has been recognized and described.⁸ That is why we opted for an anchor with a suture eyelet, which minimizes abrasion. This allows for independent suture gliding and an unproblematic use of sliding knots. An absorbable anchor is preferred because we believe that the repair of a SLAP

lesion will not need to resist superior mechanical strains.

Last, but not least, we have to consider cost issues, which might increase in importance in most countries but literally are never mentioned in the sprouting variety of technical notes. Each cannula, suture anchor, suture passer, or other disposable instrument used in an arthroscopic procedure is expensive and should not be used if the same goal can be achieved without it. Considering this, we feel that our V-type SLAP repair is not only reliable but also time- and cost-effective.

REFERENCES

1. Snyder SJ, Karzel RP, Del Pizzo W, Ferkel RD, Friedmann MJ. SLAP lesions of the shoulder. *Arthroscopy* 1990;6:274-279.
2. Barber FA, Morgan CD, Burkhart SS, Jobe CM. Current controversies: Point counterpoint. Labrum/biceps/cuff dysfunction in the throwing athlete. *Arthroscopy* 1999;15:852-857.
3. Burkhart SS, Morgan CD. SLAP lesions in the overhead athlete. *Orthop Clin North Am* 2001;32:431-441.
4. Morgan CD, Burkhart SS. Type II SLAP lesions: Three subtypes and their relationship to superior instability and rotator cuff tears. *Arthroscopy* 1998;14:553-565.
5. Snyder SJ. *Shoulder Arthroscopy*. 2nd Ed. Philadelphia: Lippincott, 2003;157-163.
6. O'Brien SJ, Allen AA, Coleman SH, Drakos MC. The transrotator cuff approach to SLAP lesions. Technical aspects for repair and clinical follow-up of 31 patients at minimum of 2 years. *Arthroscopy* 2002;18:372-377.
7. Nord KD, Masterson JP, Mauck BJ. Superior labrum anterior to posterior (SLAP) repair using the Neviaser portal. *Arthroscopy* 2004;20:S129-S133 (suppl).
8. Bardana DD, Burks RT, West JR, Greis PE. The effect of suture anchor design and orientation on suture abrasion: An in vitro study. *Arthroscopy*. 2003;19:274-281.